

Case Report

## Increased Knee Cartilage Volume in Degenerative Joint Disease using Percutaneously Implanted, Autologous Mesenchymal Stem Cells

Christopher J. Centeno, MD<sup>1,2</sup>, Dan Busse MD<sup>1</sup>, John Kisiday, PhD<sup>3</sup>, Cristin Keohan<sup>1,2</sup>, Michael Freeman, PhD<sup>4</sup>, and David Karli, MD<sup>5</sup>

From: <sup>1</sup>Regenerative Sciences Inc (RSI), <sup>2</sup>Centeno-Schultz Clinic; <sup>3</sup>Colorado State University, Fort Collins, CO; <sup>4</sup>Oregon Health Sciences University and School of Medicine; and the <sup>5</sup>Steadman Hawkins Clinic, Vail, CO.

Dr. Centeno is with Regenerative Sciences Inc (RSI), Centeno-Schultz Clinic, Westminster, CO.

Dr. Busse is with the Centeno-Schultz Clinic, Westminster, CO.

Dr. Kisiday is with Colorado State University, Fort Collins, CO.

Ms. Keohan is with the Centeno-Schultz Clinic and Regenerative Sciences Inc.

Dr. Freeman is with the Oregon Health Sciences University and School of Medicine, Salem, OR.

Dr. Karli is with Steadman Hawkins Clinic, Vail, CO.

Address correspondence:  
Dan Busse, MD  
Centeno-Schultz Clinic  
11080 Circle Point Rd  
Building 2, Suite 140  
Westminster, CO 80020  
E-mail: dan.busse@gmail.com

Disclaimer: Dr. Centeno, Dr. Busse and Ms. Koen have financial stake in Regenerative Sciences Inc. which is involved in stem cell research and treatment.  
Conflict of interest: None.

Manuscript received: 12/27/2007  
Revised manuscript received: 03/05/2008  
Accepted for publication: 04/17/2008

Free full manuscript:  
[www.painphysicianjournal.com](http://www.painphysicianjournal.com)

**Background:** The ability to repair tissue via percutaneous means may allow interventional pain physicians to manage a wide variety of diseases including peripheral joint injuries and osteoarthritis. This review will highlight the developments in cellular medicine that may soon permit interventional pain management physicians to treat a much wider variety of clinical conditions and highlight an interventional case study using these technologies

**Objective:** To determine if isolated and expanded human autologous mesenchymal stem cells could effectively regenerate cartilage and meniscal tissue when percutaneously injected into knees.

**Design:** Case Study

**Setting:** Private Interventional Pain Management practice.

**Methods:** An IRB approved study with a consenting volunteer in which mesenchymal stem cells were isolated and cultured ex-vivo from bone marrow aspiration of the iliac crest. The mesenchymal stem cells were then percutaneously injected into the subject's knee with MRI proven degenerative joint disease. Pre- and post-treatment subjective visual analog pain scores, physical therapy assessments, and MRIs measured clinical and radiographic changes.

**Results:** At 24 weeks post-injection, the patient had statistically significant cartilage and meniscus growth on MRI, as well as increased range of motion and decreased modified VAS pain scores.

**Conclusion:** The described process of autologous mesenchymal stem cell culture and percutaneous injection into a knee with symptomatic and radiographic degenerative joint disease resulted in significant cartilage growth, decreased pain and increased joint mobility in this patient. This has significant future implications for minimally invasive treatment of osteoarthritis and meniscal injury.

**Key words:** autologous mesenchymal stem cells, osteoarthritis, knee, cartilage

**Pain Physician 2008; 11:3:343-353**

Interventional pain practices in the U.S. have helped to bridge the gap between surgical solutions and conservative care such as rehabilitation. However, to date the main focus of interventional pain medicine has been spinal. Regenerative medicine has been loosely defined as the ability to regenerate tissue rather than surgically extracting or altering that tissue. The ability to repair tissue via percutaneous means may allow interventional pain physicians to manage a wide variety of diseases including peripheral joint injuries and osteoarthritis. This review will highlight the developments in cellular medicine that may soon permit interventional pain management physicians to treat a much wider variety of clinical conditions and also highlights an interventional case study using these technologies.

Regenerative medicine can be broken into 3 main areas: platelet augmentation, stem cell isolates, and recombinant growth factor amplification. Frequently these approaches have been combined. For example, adult stem cells require various growth factors to maintain their growth and engraftment (1-5). As a result, stem cells are usually transplanted with growth factors.

The platelet augmentation approach is based on the concept that platelets contain key growth factors such as Platelet Derived Growth Factors (PDGFs), Transforming Growth Factors (TGFs), Fibroblast Growth Factors (FGFs), and various forms of Interleukins (IL) (6).

### **AUTOLOGOUS PLATELET APPROACHES**

The platelet augmentation approach is based on the concept that platelets, via an intricate vesicular storage system, contain critical growth factors and mediators of tissue repair pathways. In response to tissue injury, a complex cascade of cellular and noncellular signals triggers platelet receptors, resulting in expulsion of these growth factors within the site of injury. This process is known as degranulation and initiates cellular proliferation and a tissue repair response. One of the key triggers for platelet activation is the protein thrombin, which has been shown to induce immediate platelet growth factor release in vitro in a dose dependent fashion (7).

Understanding platelet physiology has led to the concept of utilizing platelet growth factors to develop novel and natural regenerative therapies. Several commercially available centrifugation systems can isolate and concentrate platelets from an autologous blood sample. The resulting blood isolate is known as Plate-

let Rich Plasma (PRP) which contains a high concentration of stored autologous growth factors. Red blood cells are separated from PRP which typically contains a hematocrit below 5%. Most commercially available PRP centrifuge products have the ability to produce a 4 – 7 fold increase in platelet concentration compared to whole blood.

By exposing PRP to thrombin, platelet degranulation is induced and a concentrated pool of autologous growth factors in physiologic combinations can be delivered to injured tissue as a therapeutic modality to augment natural regenerative pathways. Once activated by thrombin, PRP is termed Platelet Gel (PG), due to initiation of clotting pathways mediated by fibrin in the serum.

Initial PRP studies used bovine thrombin as an activator. It has since been discovered that bovine thrombin can lead to the development of antibodies to clotting factors V, XI, and autologous thrombin. In rare case reports, this has led to systemic and life threatening coagulaopathies with multisystem failure (8). New techniques have since been developed to generate autologous thrombin from the same blood sample used to make PRP, with superior properties to bovine thrombin.

Percutaneously, PRP can be implanted into target tissue along with autologous thrombin via a double lumen injection technique. Alternatively, PRP can be activated by thrombin in vitro to produce a lower viscosity Platelet Lysate (PL) containing growth factors without platelet tissue or a fibrin matrix. PL has been successfully used as a cell culture additive to facilitate growth and differentiation of autologous mesenchymal stem cells (3,9-11).

Sound basic science and animal testing data, along with a handful of human clinical trials have demonstrated a strong safety profile and encouraging therapeutic results. Mishra and Pavelko (12) have investigated PRP injections into chronic elbow tendonosis, reporting a greater than 90% reduction in pain up to 2 years out from the intervention. Aspenberg and Virchenko (13) found that a single PRP injection into a transected rat Achilles tendon increased tissue strength by 30%, with histology showing greater maturation of tendon cells vs. control. Based on work by Anitua et al (8), the application of PG therapy has broad applications within orthopedic medicine. They hypothesize that the released growth factors have a chemotactic and mitogenic effect on mesenchymal stem cells (MSCs) and osteoblasts when applied to

bony tissues. These authors have also hypothesized other mechanisms of action in addition to recruitment of progenitor cells to replace damaged tissue, including angiogenesis, local anabolic stimulation of cellular protein synthesis, and gene expression, leading to proliferation, tissue remodeling, and production of new extracellular matrix (ECM).

### **STEM CELLS AND REGENERATIVE MEDICINE**

Embryonic stem cells have been in the popular media for many years and have shown promise scientifically while creating significant controversy. As a result, many researchers have focused on adult stem cells, or stem cells isolated from adult humans that can be transplanted into damaged tissue. Mesenchymal stem cells (MSC) are pluripotent cells found in multiple human adult tissues including bone marrow, synovial tissues, and adipose tissues. Since they are derived from the mesoderm, they have been shown to differentiate into bone, cartilage, muscle, and adipose tissue (14). Because of their multi-potent capabilities, MSC lineages have been used successfully in animal models to regenerate articular cartilage and in human models to regenerate bone (15-28). Of importance to the interventional pain management community is recent research demonstrating that articular cartilage may be able to be repaired via percutaneous introduction of MSCs (28-30).

The use of autologous adult bone marrow derived stem cells in research can again be segregated into 3 main areas: nucleated cell isolates, isolated MSCs without culture expansion, and isolated MSCs with culture expansion. Most of the adult bone marrow consists of blood cells in various stages of differentiation. These marrow components can be divided into plasma, red blood cells, platelets, and nucleated cells. The adult stem cell fraction is present in the nucleated cells of the marrow. Most of these cells are CD34+ heme progenitors (destined to differentiate into blood components), while very few are actually MSCs capable of differentiating into bone, cartilage, or muscle. In small animal models these CD34+ cells can transdifferentiate into MSCs, but in primates this does not appear to be the case (29). As a result, that leaves the small number of MSCs in the marrow as cells capable of differentiating into tissues of interest to pain medicine.

Marrow nucleated cells are used every day in regenerative orthopedics. The knee micro fracture technique popularized by Steadman et al (30) relies on the release of these cells into a cartilage lesion to initiate

fibrocartilage repair. In addition, this cell population has also been shown to assist in the repair of non-union fractures (31). For this application, bed-side centrifugation is commonly used. Again, these techniques produce a very dilute MSC population, usually a yield of 1 in 10,000 – 1,000,000 of the nucleated cells (32). Additionally, isolated bone marrow nucleated cells implanted into degenerated human peripheral joints have shown some promise for joint repair (33). Our own research in this area showed some capability of regenerating bony cortex over a hip subchondral cyst, but cartilage percutaneous replacement seemed beyond the capability of this cell population.

Since it is MSCs that are capable of differentiating into cartilage, their use as cellular building blocks that can be implanted via fluoroscopically guided percutaneous procedures has some face validity. As discussed above, the number of MSCs that can be isolated from bone marrow is fairly limited. As a result, most research in cartilage regeneration has focused on the use of culture expanded cells (34-37). This means that cells are isolated and then placed into various growth factors to be grown to higher numbers over a period of weeks in an ex-vivo monolayer culture. The most common method of isolating the very scarce MSCs from the more numerous bone marrow nucleated cells is through adhesion to plastic in tissue culture (38). MSCs will adhere to plastic, whereas the remainder of the nucleated cell population will not adhere. As a result, the adherent colonies are collected and then over several steps further “filtered” out of the larger nucleated cell population using adhesion. Once a pure MSC population is isolated, the tissue culture is transferred to monolayer, where the cells can continue to grow adherent to the plastic flask, while they are covered by a thin layer of basal nutrient media and growth factors. As the cells cover the surfaces of the plastic flasks, they are periodically removed from those surfaces with trypsin and reseeded in a greater number of flasks with new media (nutrients and growth factors). This one cycle of cell collection, seeding, and feeding is known in the cell culture vernacular as a “passage.” MSCs are usually harvested between the third and fifth passage (several weeks total culture time) and at that point have been grown to between 100 – 10,000 times more cells than harvested (39).

As discussed above, once cells are ready for reimplantation, they are usually transferred with growth factors to allow for continued cell growth and engraft-

ment to the damaged tissue. At some point, a signal is introduced (either in culture or after transplant to the damaged tissue) for the cells to differentiate into the end tissue (in this case cartilage). Various elements of the local microenvironment can affect MSC differentiation (1,18,31,40,41). Several authors have shown that nano doses of dexamethasone acts as a potent differentiating agent for MSCs toward a chondrogenic lineage (34,42,43). This concept is to be separated from clinical doses of corticosteroids, which have been shown to cause cellular apoptosis and joint destruction over time (44-48).

In addition, it's thought that a scaffolding material might be needed to allow the MSCs to attach and engraft (38-41). Many different types of scaffolding material have been used. For example, MSCs can be seeded on an allograft such as an ACL ligament (49). In addition, injectable, self-assembling scaffolds are common such as fibrin glue, hyaluronans, or mixtures of both (50,51).

### **GROWTH FACTORS IN REGENERATIVE MEDICINE**

Recombinant human growth factors have just begun to be used in modern clinical practice. These are proteins in the cytokine family that have the ability to promote growth of certain tissues. The first of these to be available in spinal surgery practices is the Bone Morphogenic Protein (BMP) family. Both BMP-2 and BMP-7 are currently being used to promote fusion. (52,53). As of yet unpublished animal trials with these growth factors may show some promise in repair of peripheral joints (54). In addition, FGF-2 has also recently been used in unpublished, small animal studies to promote disc repair. The TGF family has also shown promise in the same areas (55).

The present case study reports on a successful clinical result using percutaneously implanted, autologous culture expanded MSCs with nucleated cells and physiologic doses of dexamethasone as a differentiating agent. This patient was treated with a completely autologous processes, where mesenchymal stem cells were isolated from the iliac crest via fluoroscopically guided percutaneous procedure, ex-vivo culture expanded in a clinical lab set up for this purpose, and then reintroduced via fluoroscopy with autologous growth factors isolated from platelets and marrow nucleated cells.

### **METHODS**

The research protocol was approved through a non-profit Institutional Review Board (The Spinal Injury Foundation, Westminster CO).

Inclusion criteria were as follows:

1. Male or female patients, 18 – 65 years of age.
2. MRI evidence of degenerative knee osteoarthritis.
3. Persisting intrusive pain resulting from the condition identified in (2). To ensure that the diagnosis of intrusive osteoarthritis was accurate, diagnostic blocks were used. Confirmation that a joint was a primary cause of the patients' pain was accomplished with a fluoroscopically guided injection of 0.75% Marcaine and 4% Lidocaine into the joint space followed by complete pain relief.
4. The patients had been evaluated by a board certified orthopedic surgeon and informed that they were a knee arthroplasty candidate.

Exclusion criteria:

1. Active inflammatory or connective tissue disease (i.e. lupus, fibromyalgia, RA).
2. Active non-corrected endocrine disorder potentially associated with symptoms (i.e. hypothyroidism, diabetes).
3. Active neurologic disorder potentially associated with symptoms (i.e. peripheral neuropathy, multiple sclerosis).
4. Severe cardiac disease.
5. Pulmonary disease requiring medication usage.
6. A history of dyspnea or other reactions to transfusion of homologous blood products.

Pre-procedure data collection:

1. CBC and SMAC to rule out unknown medical condition (within 3 months of procedure).
2. The patient was surveyed for activity level.

A 46-year-old male was actively recruited by his pain physician from a private interventional pain management practice based on his diagnosis of OA causing significant ongoing pain and disability, and their willingness to proceed with the study. This patient was provided with extensive informed consent prior to being enrolled in the study.

### **PATIENT HISTORY**

The patient presented with a several year history of left greater than right knee pain he attributed to multiple injuries from parachute jumping and long

marches with heavy weights during his military service. The pain is constant, daily, 3-7/10 in intensity, and associated with "locking up" several times a month. He had 3 arthroscopic surgeries, including microfracture, on his right knee with 5 to 7 years of transient relief. His left knee, however, has undergone no surgical interventions. He has been told by his orthopaedists that his only option going forward is total knee replacements.

Physical exam of the left knee was remarkable for a slight effusion, bilateral joint line tenderness, positive McMurray's and Lachman's, and negative tests for ligamentous instability. A pre-treatment 3Tesla MRI showed degenerative joint disease.

For one week prior to the marrow harvest procedure the patient was restricted from taking corticosteroids or NSAIDs. Coincident with the marrow harvest procedure, approximately 200cc of heparinized IV venous blood was drawn to be used for PL. To prepare PL, PRP was prepared via centrifugation at 200g to separate plasma/platelets from the red blood cells. The supernatant was then drawn off and platelets pelleted at 1000g centrifugation. The platelets were then re-suspended at an approximate concentration of  $1 \times 10^9$  per mL. This was considered 100% PL, which was then diluted to between 10 – 20% as supplement for serum free cell culture media.

The patient was then placed prone on an OR table and the area to be harvested was numbed with 1% Lidocaine, and a sterile disposable trocar was used to draw 10 mL of marrow blood from the right Posterior Superior Iliac Spine area and 10 mL from the left PSIS area.

Whole marrow was centrifuged at 100g for 4 – 6 minutes to separate the plasma from the RBCs. The plasma was removed, placed in a separate tube, and centrifuged at 1000g for 10 minutes to pellet the nucleated cell fraction. The nucleated cells were washed once in PBS, counted, and then re-suspended in DMEM (Dulbecco's medium) + 10% PL and seeded at  $1 \times 10^6$  cells/cm<sup>2</sup> in monolayer flask culture. Cultures were incubated at 37°C/5% CO<sub>2</sub> in a humidified environment. The culture medium was changed after 3 days, removing the majority of the non-adherent cell population. MSC colonies developed 6 – 12 days after seeding. After growing to near confluence, the colonies were trypsinized over 2 – 3 minutes such that only the colony-forming MSCs detached. To avoid confluence, cells were harvested with 1x trypsin in DPBS (Dulbec-

co's Phosphate Buffered Saline) with 1mM EDTA (ethylene diamine tetraacetic acid) and the MSCs were reseeded at a density of 12,000 cells/cm<sup>2</sup> in  $\alpha$ MEM + 5%, 10%, or 20% PL. Primary cells derived from the bone marrow were designated as passage 0 and each subsequent reseeded of MSC was considered one further passage.

After MSCs had been grown to the fifth passage, they were suspended in PBS. The patient returned to the clinic and was consented in writing. The patient was then placed prone on a fluoroscopy table and the bilateral PSIS area was prepped with betadine and sterile drapes. The skin and deeper tissues were then anesthetized with 1% Lidocaine. A sterile trocar was then inserted under fluoroscopically guidance to the superior medial corner of the iliac wing and 50 mL of marrow was drawn. This sample was sent to the lab for nucleated cell isolation. Red blood cells were separated from the majority of nucleated cells in the whole marrow via centrifugation at 200g for 5 minutes.

The patient returned to the OR a few hours later and was placed supine with the right knee bent at 45 degrees and re-prepped using betadine and sterile gloves. A 25-gauge 2-inch needle was then inserted through a medial inferior approach under C-arm guidance. Once the joint space was attained, 0.25 mL of Isovue contrast diluted 50% with PBS was injected. Once good medial intraarticular flow was established, 22.4 million MSCs suspended in PBS were injected, followed by 1 mL of nucleated cells suspended in PBS and 1 mL of 10% PL. The patient was instructed to remain still for one hour to allow for cell attachment and then was instructed to maintain activity as tolerated. The patient returned for 2 additional 10% intraarticular knee PL injections (1 mL) at week 1 and week 2 (post-transplantation). With the 2-week post transplant PL supplementation, 1 mL of 10 ng/mL dexamethasone was also injected.

Modified VAS questionnaires and Functional Rating Index (28,29) questionnaires were provided to the patient and administered before the procedure, one month after the procedure, and 3 months after the procedure. In particular, additional VAS data was calculated by multiplying the modified numerical VAS for knee pain by the frequency of that complaint. Range of motion measurements of the knee were measured by a physical therapist

before the procedure, one month post-procedure, and 3 months post-procedure. In addition, pre-procedure MRIs were obtained on a GE 3.0 T magnet with Proton Density Fast Spin sequences in the sagittal coronal planes. Post-procedure images at one month and at 3 months were obtained using matching excitation times (NEX), repetition times (TR), and echo times (TE). Quantitative meniscus and articular cartilage volume analysis was carried out using commercially available image processing software (OSIRIS- Digital Imaging Unit, Division of Medical Informatics, University Hospital of Geneva) using 3 traces by the same examiner of each region of interest. Standard deviation from the mean was calculated for these 3 traces. The area of the medial weight bearing femoral defect was also traced and calculated in a similar manner.

**RESULTS**

Cell yields upon initial marrow harvest and processing are discussed below in Table 1. Note the disparity in the nucleated cell yield from left to right sites. Since MSCs represent approximately 1 in 10,000 nucleated marrow cells, nucleated cell yield is a likely proxy for total MSCs obtained by the marrow draw.

Table 1 shows the cell yields from marrow draw.

Table 2 shows MSC growth per day in mono-layer culture and Table 3 shows growth per passage. A passage was defined as a change of tissue culture medium.

Figures 1 and 2 show representative sagittal proton density fast spin MRI images from a GE 3.0T magnet with matching TR and TE from pre-procedure and 6 months post-procedure. Cartilage volume analysis is in Table 4.

Table 1. Cell yields from marrow draw.

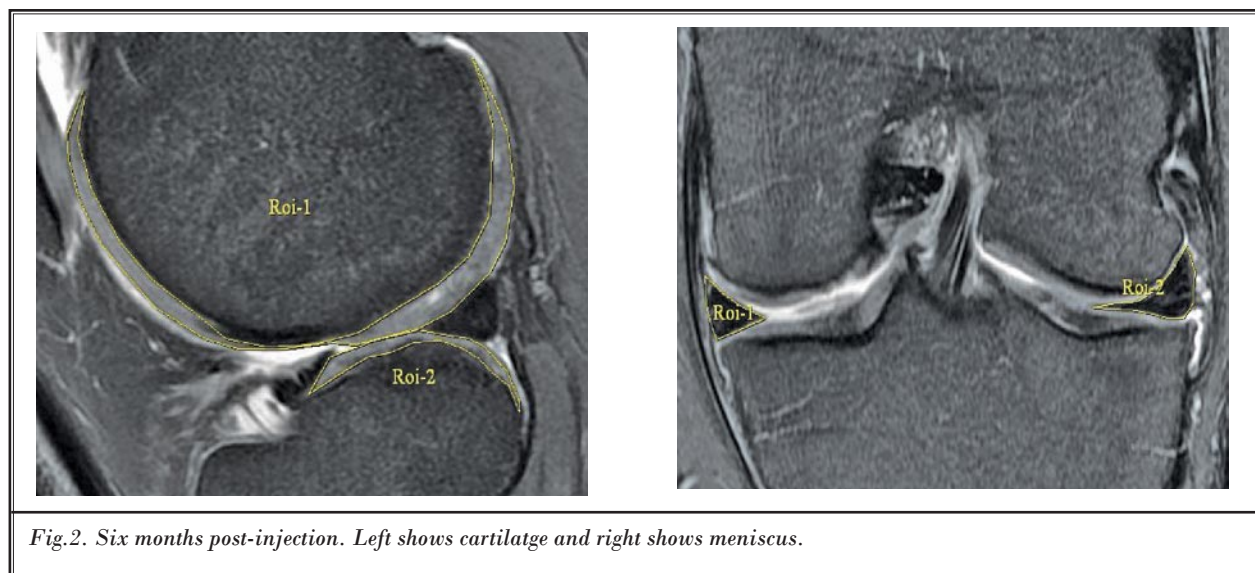
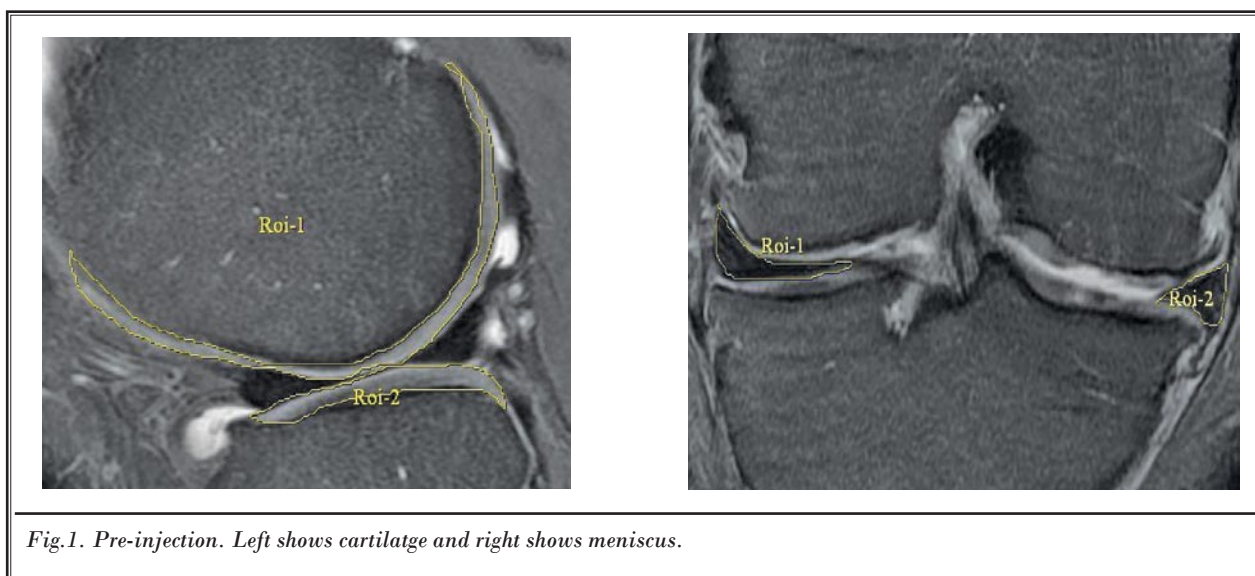
Platelet Count From Whole Blood million/ml	Marrow Draw Site	Nucleated Cell Count millions	RBC Count billions
860	Left Posterior Superior Iliac Spine	51.2	0.34
	Right Posterior Superior Iliac Spine	54.4	0.42

Table 2. MSC growth per day in millions.

Cell Growth	
Day 1	0.624
Day 2	
Day 3	2.58
Day 4	
Day 5	4.89
Day 6	
Day 7	13.23
Day 8	
Day 9	
Day 10	25.6
Day 11	<b>22.24</b>
<b>Days in colony = 10</b>	

Table 3. MSC growth in millions per tissue culture passage.

Cell Growth per Passage	
P0	0.624
P1	2.58
P2	4.89
P3	13.23



*Table 4: Cartilage volume analysis in mm<sup>3</sup>.*

Image	Area of Measurement	Volume (n = 3)	STDEV	SE	% Change from Pre-Injection
Pre-injection	Cartilage surface	4020	12.1	6.99	
	Meniscus	5178	164.57	95.13	
1 month	Cartilage surface	4924	149.01	86.13	22.49
	Meniscus	5647	453.57	262.18	9.06
3 months	Cartilage surface	4795	113.5	65.61	19.28
	Meniscus	6661	146.47	84.67	28.64

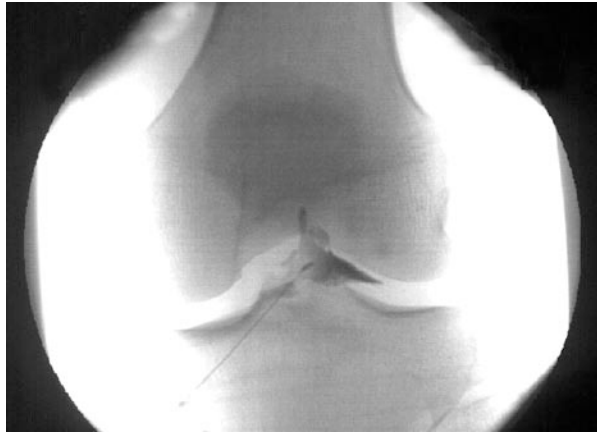

Fig. 3. Intraarticular placement of 25-gauge 2-inch Quinke needle through a medial inferior skin site. Dye flow as seen on AP fluoroscopy.

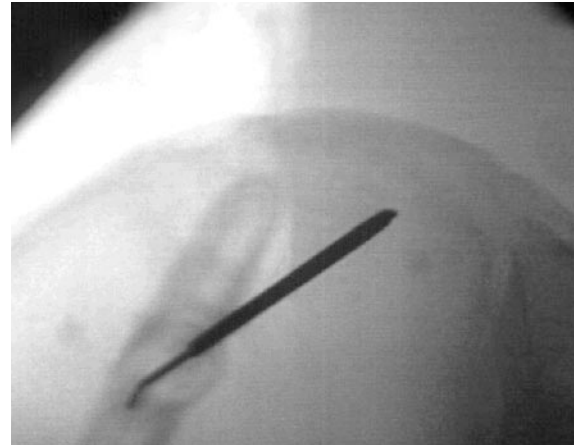


Fig. 4. Placement of the trocar into the PSIS region for bone marrow aspiration using fluoroscopic guidance.

Table 5: Patient outcomes. Functional Rating Index and Visual Analog Scores.

Outcomes Measures	Pre-Injection	4 Weeks	12 Weeks	24 Weeks
FRI	21	16	13	9
VAS	4	1.75	0.5	0.38

Table 6: Physical therapy outcomes.

Physical Therapy	Pre-Therapy	Range of Motion			
		Flexion (deg)	Flexion VAS	Extension (deg)	Extension VAS
Session	VAS Pain Score				
12 Weeks	2/10	130	1-2/10	-2	3/10
24 Weeks	0/10	135	1-2/10	+3	2/10

## DISCUSSION

The pre- and post-procedure MRI analysis demonstrated an increase in meniscus and cartilage volume that was more than the standard deviation of the 3 region of interest measurements. At 3-month follow-up, modified VAS scores decreased by 95%, from 4 to 0.38. Range of motion in extension increased from -2 degrees to +3 degrees with an associated decrease in VAS pain score.

## CONCLUSION

This case report shows MRI evidence of increased meniscus volume and femoral cartilage volume. While there has been evidence from animal models of cartilage regeneration using MSCs, this is the first case report of an increase in meniscus size in a human subject (of which we are aware). While the patient's reported clinical response could have been due to the dexamethasone injection provided post transplant procedure, the levels injected (10 ng/mL) were approximately one million times lower than those used clinically (milligram or  $1 \times 10^{-3}$  vs. nanogram or  $1 \times 10^{-9}$ ).

It should be noted that without biopsy, there is no way to determine if the change was fibrocartilage or true hyaline cartilage. Of interest, this was a "needle out/needle in" procedure with no activity restriction. Longer term follow-up of this patient will continue. Obviously, the generalizability of this technique to the larger population of patients with symptomatic osteoarthritis and traumatic knee injury is unknown.

Although no conclusion can be made from one case report, if similar findings are published from pilot studies and then larger well-designed trials, the results may have implications for interventional pain management. For example, while the laboratory expansion was carried out using specialized lab personnel, the actual clinical lab was part of an interventional pain management practice. In addition, the clinical procedures used to extract cells via fluoroscopy involved placing a sterile trocar into key bony landmarks easily visible via fluoroscopy. In addition, cell reimplantation was a simple intraarticular knee injection via fluoroscopy.

## REFERENCES

- Cassiede P, Dennis JE, Ma F, Caplan AI. Osteochondrogenic potential of marrow mesenchymal progenitor cells exposed to TGF-beta 1 or PDGF-BB as assayed in vivo and in vitro. *J Bone Miner Res* 1996; 11:1264-1273.
- Chen YJ, Wurtz T, Wang CJ, Kuo YR, Yang KD, Huang HC, Wang FS. Recruitment of mesenchymal stem cells and expression of TGF-beta 1 and VEGF in the early stage of shock wave-promoted bone regeneration of segmental defect in rats. *J Orthop Res* 2004; 22:526-534.
- Doucet, C. Ernou I, Zhang Y, Llense JR, Begot L, Holy X, Lataillade JJ. Platelet lysates promote mesenchymal stem cell expansion: A safety substitute for animal serum in cell-based therapy applications. *J Cell Physiol* 2005; 205:228-236.
- Gordon EM, Skotzko M, Kundu RK, Han B, Andrades J, Nimni M, Anderson WF, Hall FL. Capture and expansion of bone marrow-derived mesenchymal progenitor cells with a transforming growth factor-beta1-von Willebrand's factor fusion protein for retrovirus-mediated delivery of coagulation factor IX. *Hum Gene Ther* 1997; 8:1385-1394.
- Reddi AH, Cunningham NS. Bone induction by osteogenin and bone morphogenetic proteins. *Biomaterials* 1990; 11:33-34.
- Frechette JP, Martineau I, Gagnon G. Platelet-rich plasmas: Growth factor content and roles in wound healing. *J Dent Res* 2005; 84:434-439.
- Martineau I, Lacoste E, Gagnon G. Effects of calcium and thrombin on growth factor release from platelet concentrates: Kinetics and regulation of endothelial cell proliferation. *Biomaterials* 2004; 25:4489-4502.
- Anitua E, Andia I, Ardanza B, Nurden P, Nurden AT. Autologous platelets as a source of proteins for healing and tissue regeneration. *Thromb Haemost* 2004; 91:4-15.
- Bernardo ME, Avanzini MA, Perotti C, Cometa AM, Moretta A, Lenta E, Del Fante C, Novara F, de Silvestri A, Amendola G, Zuffardi O, Maccario R, Locatelli F. Optimization of in vitro expansion of human multipotent mesenchymal stromal cells for cell-therapy approaches: further insights in the search for a fetal calf serum substitute. *J Cell Physiol* 2007; 211:121-130.
- Müller I, Kordowich S, Holzwarth C, Spano C, Isensee G, Staiber A, Viebahn S, Gieseke F, Langer H, Gawaz MP, Horwitz EM, Conte P, Handgretinger R, Dominici M. Animal serum-free culture conditions for isolation and expansion of multipotent mesenchymal stromal cells from human BM. *Cytotherapy* 2006; 8:437-444.
- Schallmoser K, Bartmann C, Rohde E, Reinisch A, Kashofer K, Stadelmeyer E, Drexler C, Lanzer G, Linkesch W, Strunk D. Human platelet lysate can replace fetal bovine serum for clinical-scale expansion of functional mesenchymal stromal cells. *Transfusion*, 2007; 47:1436-1446.
- Mishra A, Pavelko T. Treatment of chronic elbow tendinosis with buffered platelet-rich plasma. *Am J Sports Med* 2006; 34:1774-1778.

13. Aspenberg P, Virchenko O. Platelet concentrate injection improves Achilles tendon repair in rats. *Acta Orthop Scand* 2004; 75:93-99.
14. Szilvassy SJ. The biology of hematopoietic stem cells. *Arch Med Res* 2003; 34:446-460.
15. Barry FP. Mesenchymal stem cell therapy in joint disease. *Novartis Found Symp*, 2003; 249:86-96; discussion 96-102, 170-174, 239-241.
16. Buckwalter JA, Mankin HJ. Articular cartilage: Degeneration and osteoarthritis, repair, regeneration, and transplantation. *Instr Course Lect*, 1998. 47:487-504.
17. Caplan AI. Mesenchymal stem cells. *J Orthop Res* 1991; 9:641-650.
18. Carter DR, Beaupré GS, Giori NJ, Helms JA. Mechanobiology of skeletal regeneration. *Clin Orthop Relat Res* 1998 (355 Suppl):S41-55.
19. Johnstone B, Yoo JU. Autologous mesenchymal progenitor cells in articular cartilage repair. *Clin Orthop Relat Res* 1999; (367 Suppl):S156-62.
20. Luyten FP. Mesenchymal stem cells in osteoarthritis. *Curr Opin Rheumatol* 2004; 16:599-603.
21. Magne D, Vinatier C, Julien M, Weiss P, Guicheux J. Mesenchymal stem cell therapy to rebuild cartilage. *Trends Mol Med* 2005; Epub (10-5-05).
22. Murphy JM, Fink DJ, Hunziker EB, Barry FP. Stem cell therapy in a caprine model of osteoarthritis. *Arthritis Rheum* 2003; 48:3464-3474.
23. Nevo Z, Robinson D, Horowitz S, Hasharoni A, Yayon A. The manipulated mesenchymal stem cells in regenerated skeletal tissues. *Cell Transplant* 1998. 7:63-70.
24. Noel D, Djouad F, Jorgense C. Regenerative medicine through mesenchymal stem cells for bone and cartilage repair. *Curr Opin Investig Drugs* 2002; 3:1000-1004.
25. Redman SN, Oldfield SF, Archer CW. Current strategies for articular cartilage repair. *Eur Cell Mater* 2005; 9:23-32; discussion 23-32.
26. Tallheden T, Dennis JE, Lennon DP, Sjögren-Jansson E, Caplan AI, Lindahl A. Phenotypic plasticity of human articular chondrocytes. *J Bone Joint Surg Am* 2003; 85-A Suppl 2:93-100.
27. Wakitani S, Goto T, Pineda SJ, Young RG, Mansour JM, Caplan AI, Goldberg VM. Mesenchymal cell-based repair of large, full-thickness defects of articular cartilage. *J Bone Joint Surg Am* 1994; 76:579-592.
28. Walsh CJ, Goodman D, Caplan AI, Goldberg VM. Meniscus regeneration in a rabbit partial meniscectomy model. *Tissue Eng* 1999; 5:327-337.
29. Keyser KA, Morris JC, Kiem HP. Genetically modified CD34+ cells do not contribute to the mesenchymal compartment after autologous transplantation in the baboon. *Cytotherap* 2005; 7:345-352.
30. Steadman JR, Ramappa AJ, Maxwell RB, Briggs KK. An arthroscopic treatment regimen for osteoarthritis of the knee. *Arthroscopy* 2007; 23:948-955.
31. Bruder SP, Fink DJ, Caplan AI. Mesenchymal stem cells in bone development, bone repair, and skeletal regeneration therapy. *J Cell Biochem* 1994; 56:283-294.
32. D'ippolito G, Schiller PC, Ricordi C, Roos BA, Howard GA. Age-related osteogenic potential of mesenchymal stromal stem cells from human vertebral bone marrow. *J Bone Miner Res* 1999; 14:1115-1122.
33. Centeno CJ, Kisiday J, Freeman M, Schultz JR. Partial regeneration of the human hip via autologous bone marrow nucleated cell transfer: A case study. *Pain Physician* 2006; 9:253-256.
34. Bosnakovski D, Mizuno M, Kim G, Takagi S, Okumura M, Fujinaga T. Chondrogenic differentiation of bovine bone marrow mesenchymal stem cells (MSCs) in different hydrogels: Influence of collagen type II extracellular matrix on MSC chondrogenesis. *Biotechnol Bioeng* 2006; 93:1152-1163.
35. Gao J, Caplan AI. Mesenchymal stem cells and tissue engineering for orthopaedic surgery. *Chir Organi Mov* 2003; 88:305-316.
36. Guo X, Wang C, Zhang Y, Xia R, Hu M, Duan C, Zhao Q, Dong L, Lu J, Qing Song Y. Repair of large articular cartilage defects with implants of autologous mesenchymal stem cells seeded into beta-tricalcium phosphate in a sheep model. *Tissue Eng* 2004; 10:1818-1829.
37. Xiang Y, Zheng Q, Jia BB, Huang GP, Xu YL, Wang JF, Pan ZJ. Ex vivo expansion and pluripotential differentiation of cryopreserved human bone marrow mesenchymal stem cells. *J Zhejiang Univ Sci B* 2007; 8:136-146.
38. Pereira RF, Halford KW, O'Hara MD, Leeper DB, Sokolov BP, Pollard MD, Bagasra O, Prockop DJ. Cultured adherent cells from marrow can serve as long-lasting precursor cells for bone, cartilage, and lung in irradiated mice. *Proc Natl Acad Sci USA* 1995; 92:4857-4861.
39. Crisostomo PR, Wang M, Wairiuko GM, Morrell ED, Terrell AM, Seshadri P, Nam UH, Meldrum DR. High passage number of stem cells adversely affects stem cell activation and myocardial protection. *Shock* 2006; 26:575-580.
40. Cui JH, Park K, Park SR, Min BH. Effects of low-intensity ultrasound on chondrogenic differentiation of mesenchymal stem cells embedded in polyglycolic acid: An in vivo study. *Tissue Eng* 2006; 12:75-82.
41. Risbud MV, Albert TJ, Guttapalli A, Vresilovic EJ, Hillibrand AS, Vaccaro AR, Shapiro IM. Differentiation of mesenchymal stem cells towards a nucleus pulposus-like phenotype in vitro: Implications for cell-based transplantation therapy. *Spine* 2004; 29:(2627-2632).
42. Scutt A, Bertram P. Basic fibroblast growth factor in the presence of dexamethasone stimulates colony formation, expansion, and osteoblastic differentiation by rat bone marrow stromal cells. *Calcif Tissue Int* 1999; 64:69-77.
43. Zhang Y, Wang C, Liao W, Li Z, Guo X, Zhao Q, Duan C, Xia R. In vitro chondrogenic phenotype differentiation of bone marrow-derived mesenchymal stem cells. *J Huazhong Univ Sci Technol Med Sci* 2004; 24:275-278.
44. Chrysis D, Ritzen EM, Savendahl L. Growth retardation induced by dexamethasone is associated with increased apoptosis of the growth plate chondrocytes. *J Endocrinol* 2003; 176:331-337.
45. Chrysis D, Zaman F, Chagin AS, Takigawa M, Sävendahl L. Dexamethasone induces apoptosis in proliferative chondrocytes through activation of caspases and suppression of the Akt-phosphatidylinositol 3'-kinase signaling pathway. *Endocrinology* 2005;

- 146:1391-1397.
46. D'Lima DD, Hashimoto S, Chen PC, Lotz MK, Colwell CW Jr. Prevention of chondrocyte apoptosis. *J Bone Joint Surg Am* 2001; 83-A Suppl 2(Pt 1):25-26.
  47. Jones LC, Hungerford DS. The pathogenesis of osteonecrosis. *Instr Course Lect* 2007; 56:179-196.
  48. Nakazawa F, Matsuno H, Yudoh K, Watanabe Y, Katayama R, Kimura T. Corticosteroid treatment induces chondrocyte apoptosis in an experimental arthritis model and in chondrocyte cultures. *Clin Exp Rheumatol* 2002; 20:773-781.
  49. Li F, Jia H, Yu C. ACL reconstruction in a rabbit model using irradiated Achilles allograft seeded with mesenchymal stem cells or PDGF-B gene-transfected mesenchymal stem cells. *Knee Surg Sports Traumatol Arthrosc* 2007; 15:1219-1227.
  50. Silverman RP, Passaretti D, Huang W, Randolph MA, Yaremchuk MJ. Injectable tissue-engineered cartilage using a fibrin glue polymer. *Plast Reconstr Surg* 1999; 103:1809-1818.
  51. Radice M, Brun P, Cortivo R, Scapinelli R, Battaliard C, Abatangelo G. Hyaluronan-based biopolymers as delivery vehicles for bone-marrow-derived mesenchymal progenitors. *J Biomed Mater Res* 2000; 50:101-109.
  52. Hamilton DK, Jones-Quaidoo SM, Sansur C, Shaffrey CI, Oskouian R, Jane JA Sr. Outcomes of bone morphogenetic protein-2 in mature adults: Posterolateral non-instrument-assisted lumbar decompression and fusion. *Surg Neurol* 2008; 69:457-461.
  53. White AP, Vaccaro AR, Hall JA, Whang PG, Friel BC, McKee MD. Clinical applications of BMP-7/OP-1 in fractures, nonunions and spinal fusion. *Int Orthop* 2007; 31:735-741.
  54. Ishii I, Mizuta H, Sei A, Hirose J, Kudo S, Hiraki Y. Healing of full-thickness defects of the articular cartilage in rabbits using fibroblast growth factor-2 and a fibrin sealant. *J Bone Joint Surg Br* 2007; 89:693-700.
  55. Blaney Davidson EN, van der Kraan PM, van den Berg WB. TGF-beta and osteoarthritis. *Osteoarthritis Cartilage* 2007; 15:597-604.

